

## Quality ID #405: Appropriate Follow-up Imaging for Incidental Abdominal Lesions

### **2024 COLLECTION TYPE:** **MEDICARE PART B CLAIMS**

### **MEASURE TYPE:** Process – High Priority

### **DESCRIPTION:**

Percentage of final reports for imaging studies for patients aged 18 years and older with one or more of the following noted incidentally with a specific recommendation for no follow-up imaging recommended based on radiological findings:

- Cystic renal lesion that is simple appearing\* (*Bosniak I or II*)
- Adrenal lesion less than or equal to 1.0 cm
- Adrenal lesion greater than 1.0 cm but less than or equal to 4.0 cm classified as likely benign or diagnostic benign by unenhanced CT or washout protocol CT, or MRI with in- and opposed-phase sequences or other equivalent institutional imaging protocols

### **INSTRUCTIONS:**

This measure is to be submitted **each time** a patient undergoes an imaging study with an incidental abdominal lesion finding during the performance period. There is no diagnosis associated with this measure. It is anticipated that Merit-based Incentive Payment System (MIPS) eligible clinicians who provide the professional component of diagnostic imaging studies will submit this measure.

### **Measure Submission Type:**

Measure data may be submitted by individual MIPS eligible clinicians using Medicare Part B claims. The listed denominator criteria are used to identify the intended patient population. The numerator quality data codes included in this specification are used to submit the quality actions allowed by the measure on the claim form(s). All measure-specific coding should be submitted on the claim(s) representing the denominator eligible encounter and selected numerator option.

### **DENOMINATOR:**

All final reports for imaging studies for patients aged 18 years and older with one or more of the following incidentally noted:

- Cystic renal lesion that is simple appearing\* (*Bosniak I or II*)  
or
- Adrenal lesion less than or equal to 1.0 cm  
or
- Adrenal lesion greater than 1.0 cm but less than or equal to 4.0 cm classified as likely benign or diagnostic benign by unenhanced CT or washout protocol CT, or MRI with in- and opposed-phase sequences or other equivalent institutional imaging protocols

***DENOMINATOR NOTE:*** *The intent of this measure is to ensure patients with incidental findings that are highly likely to be benign do not receive follow up imaging routinely.*

\* "Simple-appearing criteria":

- *Incidental renal mass on non-contrast enhanced abdominal CT that does not contain fat, is homogenous in appearance, -10-20 HU or  $\geq 70$  HU. (ACR, 2017)*

- *Incidental renal mass on contrast-enhanced abdominal CT that does not contain fat, is homogenous in appearance, -10-20 HU. (ACR, 2017)*

When reporting this measure, masses and lesions that do not meet all the criteria for “no further work-up” as provided in [Management of the Incidental Renal Mass on CT: A White Paper of the ACR Incidental Findings Committee](#) or the [Management of the Incidental Adrenal Mass on CT: A White Paper of the ACR Incidental Findings Committee](#) should not be considered in the context or intent of this measure. However, generally accepted radiology practices should be followed with respect to communication and management of any characteristically benign findings. A measure performance goal of 100% should not substitute for clinical judgment in individual cases.

**Denominator Criteria (Eligible Cases):**

Patients aged ≥ 18 years on date of encounter

**AND**

**Patient procedure during the performance period (CPT):** 71250, 71260, 71270, 71271, 71275, 71555, 72131, 72191, 72192, 72193, 72194, 72195, 72196, 72197, 72198, 74150, 74160, 74170, 74176, 74177, 74178, 74181, 74182, 74183

**WITHOUT**

**Telehealth Modifier (including but not limited to):** GQ, GT, 95, POS 02, POS 10

**NUMERATOR:**

Final reports for imaging studies that include a description of incidental cystic renal lesion or adrenal lesion stating follow-up imaging is **not** recommended

**Numerator Instructions:**

A short note can be made in the final report, such as:

"No follow-up imaging is recommended as incidental lesions are likely benign" or

"No follow-up imaging is recommended per consensus recommendations based on imaging criteria. Further lab evaluation could be pursued based on clinical findings"

**Numerator Quality Data Coding Options:**

**Final Report without Incidental Finding**

(One G-code [G9551] is required on the claim form to submit this numerator option)

**Denominator Exclusion: G9551:**

Final reports for imaging studies without an incidentally found lesion noted:

- *Cystic renal lesion that is simple appearing\* (Bosniak I or II)*
- *Adrenal lesion less than or equal to 1.0 cm*
- *Adrenal lesion greater than 1.0 cm but less than or equal to 4.0 cm classified as likely benign by unenhanced CT or washout protocol CT, or MRI with in- and opposed-phase sequences or other equivalent institutional imaging protocols*

\*“Simple-appearing criteria”:

- *Incidental renal mass on non-contrast enhanced abdominal CT that does not contain fat, is homogenous in appearance, -10-20 HU or ≥70 HU.*

**OR**

**Final Reports with Follow-Up Imaging Not Recommended**

(Two G-codes [G9548 & G9547] are required on the claim form to submit this numerator option)

**Performance Met: G9548:**

Final reports for imaging studies stating no follow-up imaging is recommended

**AND**

**G9547:**

Incidentally found lesion noted:

- *Cystic renal lesion that is simple appearing\* (Bosniak I or II)*
- *Adrenal lesion less than or equal to 1.0 cm*
- *Adrenal lesion greater than 1.0 cm but less than or equal to 4.0 cm classified as likely benign by unenhanced CT or washout protocol CT, or MRI with in- and opposed-phase sequences or other equivalent institutional imaging protocols*

*\*"Simple-appearing criteria":*

- *Incidental renal mass on non-contrast enhanced abdominal CT that does not contain fat, is homogenous in appearance, -10-20 HU or  $\geq 70$  HU.*

**OR**

**Documenting Medical Reason(s) for Recommending Follow-Up**

(Two G-codes [G9549 & G9547] are required on the claim form to submit this numerator option)

**Denominator Exception: G9549:**

Documentation of medical reason(s) that follow-up imaging is indicated (e.g., patient has lymphadenopathy, signs of metastasis or an active diagnosis or history of cancer, and other medical reason(s))

**AND**

**G9547:**

Incidentally found lesion noted:

- *Cystic renal lesion that is simple appearing\* (Bosniak I or II)*
- *Adrenal lesion less than or equal to 1.0 cm*
- *Adrenal lesion greater than 1.0 cm but less than or equal to 4.0 cm classified as likely benign by unenhanced CT or washout protocol CT, or MRI with in- and opposed-phase sequences or other equivalent institutional imaging protocols*

*\*"Simple-appearing criteria":*

- *Incidental renal mass on non-contrast enhanced abdominal CT that does not contain fat, is homogenous in appearance, -10-20 HU or  $\geq 70$  HU.*

**OR**

**Final Reports with Follow-Up Imaging Recommended, or with No Recommendation**

(Two G-codes [G9550 & G9547] are required on the claim form to submit this numerator option)

**Performance Not Met: G9550:**

Final reports for imaging studies with follow-up imaging recommended, or final reports that do not include a specific recommendation of no follow-up

**AND**

**G9547:**

Incidentally found lesion noted:

- Cystic renal lesion that is simple appearing\* (Bosniak I or II)
- Adrenal lesion less than or equal to 1.0 cm
- Adrenal lesion greater than 1.0 cm but less than or equal to 4.0 cm classified as likely benign by unenhanced CT or washout protocol CT, or MRI with in- and opposed-phase sequences or other equivalent institutional imaging protocols

\*“Simple-appearing criteria”:

- Incidental renal mass on non-contrast enhanced abdominal CT that does not contain fat, is homogenous in appearance,  $-10-20$  HU or  $\geq 70$  HU.

### **RATIONALE:**

Incidental renal, and adrenal lesions are commonly found during imaging studies, with most of the findings being benign. Given the low rate of malignancy, unnecessary follow-up procedures are costly and present a significant burden to patients. To avoid excessive testing and costs, follow-up is not recommended for these small lesions.

### **CLINICAL RECOMMENDATION STATEMENTS:**

The ACR Incidental Findings Committee recommends the following considerations for incidental renal masses:

#### Overview:

Incidental renal masses are a common problem in imaging; an algorithm is provided to guide management of the incidental renal mass based on imaging features.

- Key properties of the algorithm include (1) guidance based on the CT examination on which the mass was detected; (2) guidance for solid, cystic, and fat-containing masses; (3) acknowledgment that many renal masses that are too small to characterize (TSTC) are either benign or otherwise insignificant; (4) incorporation of renal mass biopsy as a diagnostic tool; and (5) surveillance of subcentimeter solid renal masses.
  - The importance of shared decision making between patients and physicians is emphasized, particularly in patients with limited life expectancy and comorbidities
- 1) Although most renal masses on unenhanced CT are incompletely characterized, a homogenous lesion between  $-10$  and  $20$  HU is highly likely to be a benign cyst. (ACR, 2017)
  - 2) Although the majority of lesions are characterized on initial imaging, one definition for the indeterminate renal mass is a lesion containing areas that measure  $20-70$  Hounsfield units (HU) on noncontrast imaging. Homogenous lesions measuring  $<20$  HU or  $>70$  HU can be considered benign, whereas lesions either entirely or partially within the  $20-70$  HU range should be considered indeterminate and warrant further evaluation. (ACR, 2015)
  - 3) A homogenous lesion  $70$  HU or greater on unenhanced CT can confidently be diagnosed as a hyperdense Bosniak II cyst requiring no further characterization or treatment. Further characterization of these masses would add anxiety and cost and is unlikely to alter the diagnosis. (ACR, 2017)
  - 4) The hyperdense cyst can present a diagnostic problem in that its initial attenuation coefficients are high, which can theoretically obscure tiny papillary projections along its wall. However, a homogenous renal mass measuring  $>70$  HU at unenhanced CT has been shown to have a  $>99.9\%$  chance of representing a high-attenuation renal cyst rather than RCC. (ACR, 2015)

- 5) Any homogenous renal mass on contrast-enhanced CT between -10 and 20 HU is a benign simple cyst, not requiring further evaluation. (ACR, 2017)
- 6) For a lesion characterized as a cystic renal mass, that is, one predominantly consisting of homogenous round or oval regions without measurable enhancement, we advocate using the Bosniak classification system. Bosniak I and II cystic masses are reliably considered benign and need no follow up. (ACR, 2017)
- 7) Although there are no data to suggest how to manage very small (<1 cm) renal masses, some feel that if the lesion in question appears to be a simple cyst—i.e., a low-attenuation (0-20 HU) mass containing no septations, nodularity, calcifications, or enhancement—it can be presumed to be benign and need not be further pursued. (ACR, 2015)
- 8) Refer to the [Management of Incidental Renal Masses: A White Paper of the ACR Incidental Findings Committee](https://www.jacr.org/article/S1546-1440(17)30497-0/pdf) (2017) [https://www.jacr.org/article/S1546-1440\(17\)30497-0/pdf](https://www.jacr.org/article/S1546-1440(17)30497-0/pdf) for further detailed guidance

The ACR Incidental Findings Committee Adrenal Subcommittee for management of incidental adrenal recommends the following for unenhanced CT, or washout protocol CT, or MRI with in- and opposed-phase sequences or equivalent protocols examinations for adrenal masses :

- 1) If an adrenal mass has diagnostic features of a benign lesion such as a myelolipoma (presence of macroscopic fat) or cyst (simple cyst-appearing without enhancement), no additional workup or follow-up imaging is needed.
- 2) If the lesion is 1 to 4 cm and has a density of  $\leq 10$  HU on CT or signal loss compared with the spleen on out-of-phase images of a chemical-shift MRI (CS-MRI) examination, it is almost always diagnostic of a lipid-rich adenoma. If there are no diagnostic benign imaging features but the adrenal mass has been stable for  $\geq 1$  year or longer, it is very likely benign requiring no additional imaging. (ACR, 2017)
- 3) Refer to the [Management of Incidental Adrenal Masses: A White Paper of the ACR Incidental Findings Committee](https://www.jacr.org/article/S1546-1440(17)30551-3/pdf) (2017) [https://www.jacr.org/article/S1546-1440\(17\)30551-3/pdf](https://www.jacr.org/article/S1546-1440(17)30551-3/pdf) for further detailed guidance.

#### **COPYRIGHT:**

The Measure is not a clinical guideline, does not establish a standard of medical care, and has not been tested for all potential applications.

The Measure, while copyrighted, can be reproduced and distributed, without modification, for noncommercial purposes, e.g., use by health care providers in connection with their practices. Commercial use is defined as the sale, license, or distribution of the Measure for commercial gain, or incorporation of the Measure into a product or service that is sold, licensed or distributed for commercial gain.

Commercial uses of the Measure require a license agreement between the user and the American College of Radiology (ACR). Neither ACR nor its members shall be responsible for any use of the Measure.

The PCPI's and AMA's significant past efforts and contributions to the development and updating of the Measures are acknowledged. ACR is solely responsible for the review and enhancement ("Maintenance") of the Measure as of August 1, 2020.

ACR encourages use of the Measure by other health care professionals, where appropriate.

**THE MEASURE AND SPECIFICATIONS ARE PROVIDED "AS IS" WITHOUT WARRANTY OF ANY KIND.**

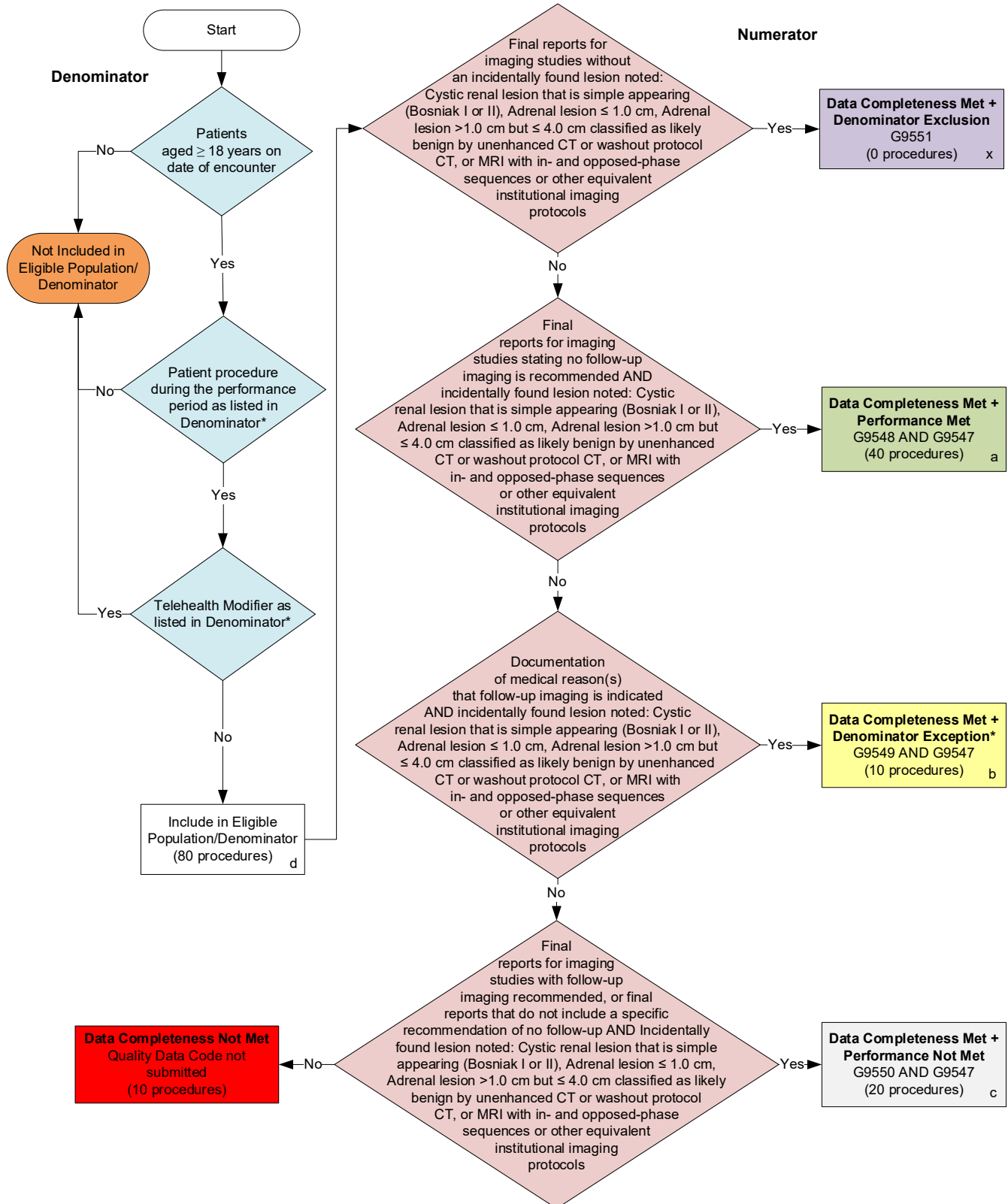
©2023 American College of Radiology. All Rights Reserved. Applicable FARS/DFARS Restrictions Apply to Government Use.

Limited proprietary coding may be contained in the Measure specifications for convenience. A license agreement must be entered prior to a third party's use of Current Procedural Terminology (CPT®) or other proprietary code set contained in the Measures. Any other use of CPT or other coding by the third party is strictly prohibited. ACR and its members disclaim all liability for use or accuracy of any CPT or other coding contained in the specifications.

CPT® contained in the Measures specifications is copyright 2004-2023 American Medical Association. LOINC® copyright 2004-2023 Regenstrief Institute, Inc. SNOMED CLINICAL TERMS (SNOMED CT®) copyright 2004-2023. The International Health Terminology Standards Development Organisation (IHTSDO). ICD-10 is copyright 2023 World Health Organization. All Rights Reserved.

## 2024 Medicare Part B Claims Flow for Quality ID #405: Appropriate Follow-up Imaging for Incidental Abdominal Lesions

*Disclaimer: Refer to the measure specification for specific coding and instructions to submit this measure*



### **SAMPLE CALCULATIONS**

**Data Completeness=**

$$\frac{\text{Denominator Exclusion (x=0)} + \text{Performance Met (a=40)} + \text{Denominator Exception (b=10)} + \text{Performance Not Met (c=20)}}{\text{Eligible Population / Denominator (d=80 procedures)}} = \frac{70 \text{ procedures}}{80 \text{ procedures}} = 87.50\%$$

**Performance Rate=**

$$\frac{\text{Performance Met (a=40 procedures)}}{\text{Data Completeness Numerator (70) - Denominator Exclusion (x=0) - Denominator Exception (b=10)}} = \frac{40 \text{ procedures}}{60 \text{ procedures}} = 66.67\%$$

\*See the posted measure specification for specific coding and instructions to submit this measure.

NOTE: Submission Frequency: Procedure

CPT only copyright 2023 American Medical Association. All rights reserved.  
The measure diagrams were developed by CMS as a supplemental resource to be used in conjunction with the measure specifications. They should not be used alone or as a substitution for the measure specification.

v8



## 2024 Medicare Part B Claims Flow Narrative for Quality ID #405: Appropriate Follow-up Imaging for Incidental Abdominal Lesions

**Disclaimer:** Please refer to the measure specification for specific coding and instructions to submit this measure.

1. Start with Denominator
2. Check *Patients aged greater than or equal to 18 years on date of encounter*.
  - a. If *Patients aged greater than or equal to 18 years on date of encounter* equals No, do not include in *Eligible Population/Denominator*. Stop processing.
  - b. If *Patients aged greater than or equal to 18 years on date of encounter* equals Yes, proceed to check *Patient procedure during the performance period as listed in Denominator\**.
3. Check *Patient procedure during the performance period as listed in Denominator\**.
  - a. If *Patient procedure during the performance period as listed in Denominator\** equals No, do not include in *Eligible Population/Denominator*. Stop processing.
  - b. If *Patient procedure during the performance period as listed in Denominator\** equals Yes, proceed to check *Telehealth Modifier as listed in Denominator\**.
4. Check *Telehealth Modifier as listed in Denominator\**.
  - a. If *Telehealth Modifier as listed in Denominator\** equals Yes, do not include in *Eligible Population/Denominator*. Stop processing.
  - b. If *Telehealth Modifier as listed in Denominator\** equals No, include in *Eligible Population/Denominator*.
5. Denominator Population:
  - Denominator Population is all Eligible Procedures in the Denominator. Denominator is represented as Denominator in the Sample Calculation listed at the end of this document. Letter d equals 80 procedures in the Sample Calculation.
6. Start Numerator
7. Check *Final reports for imaging studies without an incidentally found lesion noted: Cystic renal lesion that is simple appearing (Bosniak I or II), Adrenal lesion less than or equal to 1.0 cm, Adrenal lesion greater than 1.0 cm but less than or equal to 4.0 cm classified as likely benign by unenhanced CT or washout protocol CT, or MRI with in- and opposed-phase sequences or other equivalent institutional imaging protocols*.
  - a. If *Final reports for imaging studies without an incidentally found lesion noted: Cystic renal lesion that is simple appearing (Bosniak I or II), Adrenal lesion less than or equal to 1.0 cm, Adrenal lesion greater than 1.0 cm but less than or equal to 4.0 cm classified as likely benign by unenhanced CT or washout protocol CT, or MRI with in- and opposed-phase sequences or other equivalent institutional imaging protocols* equals Yes, include in *Data Completeness Met and Denominator Exclusion*.
    - *Data Completeness Met and Denominator Exclusion* letter is represented in the Data Completeness and Performance Rate in the Sample Calculation listed at the end of this document. Letter x equals 0 procedures in the Sample Calculation.
  - b. If *Final reports for imaging studies without an incidentally found lesion noted: Cystic renal lesion that is simple appearing (Bosniak I or II), Adrenal lesion less than or equal to 1.0 cm, Adrenal lesion greater than 1.0 cm but less than or equal to 4.0 cm classified as likely benign by unenhanced CT or washout protocol*

CT, or MRI with in- and opposed-phase sequences or other equivalent institutional imaging protocols equals No, proceed to check *Final reports for imaging studies stating no follow-up imaging is recommended AND incidentally found lesion noted: Cystic renal lesion that is simple appearing (Bosniak I or II), Adrenal lesion less than or equal to 1.0 cm, Adrenal lesion greater than 1.0 cm but less than or equal to 4.0 cm classified as likely benign by unenhanced CT or washout protocol CT, or MRI with in- and opposed-phase sequences or other equivalent institutional imaging protocols.*

8. Check *Final reports for imaging studies stating no follow-up imaging is recommended AND incidentally found lesion noted: Cystic renal lesion that is simple appearing (Bosniak I or II), Adrenal lesion less than or equal to 1.0 cm, Adrenal lesion greater than 1.0 cm but less than or equal to 4.0 cm classified as likely benign by unenhanced CT or washout protocol CT, or MRI with in- and opposed-phase sequences or other equivalent institutional imaging protocols:*
  - a. If *Final reports for imaging studies stating no follow-up imaging is recommended AND incidentally found lesion noted: Cystic renal lesion that is simple appearing (Bosniak I or II), Adrenal lesion less than or equal to 1.0 cm, Adrenal lesion greater than 1.0 cm but less than or equal to 4.0 cm classified as likely benign by unenhanced CT or washout protocol CT, or MRI with in- and opposed-phase sequences or other equivalent institutional imaging protocols equals Yes, include in Data Completeness Met and Performance Met.*
    - *Data Completeness Met and Performance Met* letter is represented in the Data Completeness and Performance Rate in the Sample Calculation listed at the end of this document. Letter a equals 40 procedures in the Sample Calculation.
  - b. If *Final reports for imaging studies stating no follow-up imaging is recommended AND incidentally found lesion noted: Cystic renal lesion that is simple appearing (Bosniak I or II), Adrenal lesion less than or equal to 1.0 cm, Adrenal lesion greater than 1.0 cm but less than or equal to 4.0 cm classified as likely benign by unenhanced CT or washout protocol CT, or MRI with in- and opposed-phase sequences or other equivalent institutional imaging protocols equals No, proceed to check Documentation of medical reason(s) that follow-up imaging is indicated AND incidentally found lesion noted: Cystic renal lesion that is simple appearing (Bosniak I or II), Adrenal lesion less than or equal to 1.0 cm, Adrenal lesion greater than 1.0 cm but less than or equal to 4.0 cm classified as likely benign by unenhanced CT or washout protocol CT, or MRI with in- and opposed-phase sequences or other equivalent institutional imaging protocols.*
9. Check *Documentation of medical reason(s) that follow-up imaging is indicated AND incidentally found lesion noted: Cystic renal lesion that is simple appearing (Bosniak I or II), Adrenal lesion less than or equal to 1.0 cm, Adrenal lesion greater than 1.0 cm but less than or equal to 4.0 cm classified as likely benign by unenhanced CT or washout protocol CT, or MRI with in- and opposed-phase sequences or other equivalent institutional imaging protocols:*
  - a. If *Documentation of medical reason(s) that follow-up imaging is indicated AND incidentally found lesion noted: Cystic renal lesion that is simple appearing (Bosniak I or II), Adrenal lesion less than or equal to 1.0 cm, Adrenal lesion greater than 1.0 cm but less than or equal to 4.0 cm classified as likely benign by unenhanced CT or washout protocol CT, or MRI with in- and opposed-phase sequences or other equivalent institutional imaging protocols equals Yes, include in Data Completeness Met and Denominator Exception.*
    - *Data Completeness Met and Denominator Exception* letter is represented in the Data Completeness and Performance Rate in the Sample Calculation listed at the end of this document. Letter b equals 10 procedures in the Sample Calculation.
  - b. If *Documentation of medical reason(s) that follow-up imaging is indicated AND incidentally found lesion noted: Cystic renal lesion that is simple appearing (Bosniak I or II), Adrenal lesion less than or equal to 1.0 cm, Adrenal lesion greater than 1.0 cm but less than or equal to 4.0 cm classified as likely benign by unenhanced CT or washout protocol CT, or MRI with in- and opposed-phase sequences or other*

*equivalent institutional imaging protocols equals No, proceed to check Final reports for imaging studies with follow-up imaging recommended, or final reports that do not include a specific recommendation of no follow-up AND Incidentally found lesion noted: Cystic renal lesion that is simple appearing (Bosniak I or II), Adrenal lesion less than or equal to 1.0 cm, Adrenal lesion greater than 1.0 cm but less than or equal to 4.0 cm classified as likely benign by unenhanced CT or washout protocol CT, or MRI with in- and opposed-phase sequences or other equivalent institutional imaging protocols.*

10. Check *Final reports for imaging studies with follow-up imaging recommended, or final reports that do not include a specific recommendation of no follow-up AND Incidentally found lesion noted: Cystic renal lesion that is simple appearing (Bosniak I or II), Adrenal lesion less than or equal to 1.0 cm, Adrenal lesion greater than 1.0 cm but less than or equal to 4.0 cm classified as likely benign by unenhanced CT or washout protocol CT, or MRI with in- and opposed-phase sequences or other equivalent institutional imaging protocols:*

a. If *Final reports for imaging studies with follow-up imaging recommended, or final reports that do not include a specific recommendation of no follow-up AND Incidentally found lesion noted: Cystic renal lesion that is simple appearing (Bosniak I or II), Adrenal lesion less than or equal to 1.0 cm, Adrenal lesion greater than 1.0 cm but less than or equal to 4.0 cm classified as likely benign by unenhanced CT or washout protocol CT, or MRI with in- and opposed-phase sequences or other equivalent institutional imaging protocols equals Yes, include in Data Completeness Met and Performance Not Met.*

- *Data Completeness Met and Performance Not Met letter is represented in the Data Completeness in the Sample Calculation listed at the end of this document. Letter c equals 20 procedures in the Sample Calculation.*

b. If *Final reports for imaging studies with follow-up imaging recommended, or final reports that do not include a specific recommendation of no follow-up AND Incidentally found lesion noted: Cystic renal lesion that is simple appearing (Bosniak I or II), Adrenal lesion less than or equal to 1.0 cm, Adrenal lesion greater than 1.0 cm but less than or equal to 4.0 cm classified as likely benign by unenhanced CT or washout protocol CT, or MRI with in- and opposed-phase sequences or other equivalent institutional imaging protocols equals No, proceed to check Data Completeness Not Met.*

11. Check *Data Completeness Not Met:*

- If *Data Completeness Not Met, the Quality Data Code was not submitted. 10 procedures have been subtracted from the Data Completeness Numerator in the Sample Calculation.*

### **Sample Calculations**

Data Completeness equals Denominator Exclusion (x equals 0 procedures) plus Performance Met (a equals 40 procedures) plus Denominator Exception (b equals 10 procedures) plus Performance Not Met (c equals 20 procedures) divided by Eligible Population/Denominator (d equals 80 procedures). All equals 70 procedures divided by 80 procedures. All equals 87.50 percent.

Performance Rate equals Performance Met (a equals 40 procedures) divided by Data Completeness Numerator (70 procedures) minus Denominator Exclusion (x equals 0 procedures) minus Denominator Exception (b equals 10 procedures). All equals 40 procedures divided by 60 procedures. All equals 66.67 percent.

\*See the posted measure specification for specific coding and instructions to submit this measure.

NOTE: Submission Frequency: Procedure

The measure diagrams were developed by CMS as a supplemental resource to be used in conjunction with the measure specifications. They should not be used alone or as a substitution for the measure specification.